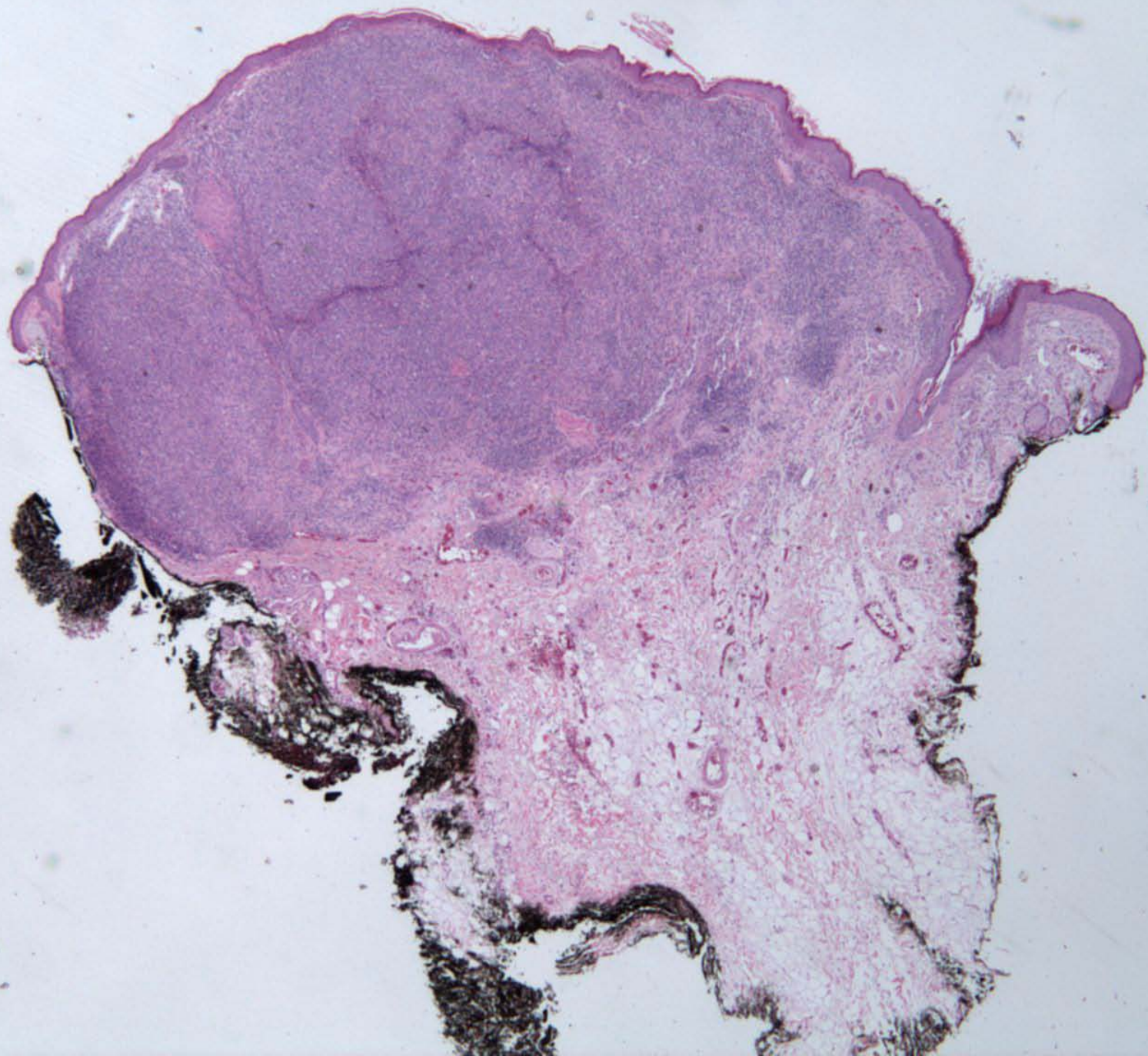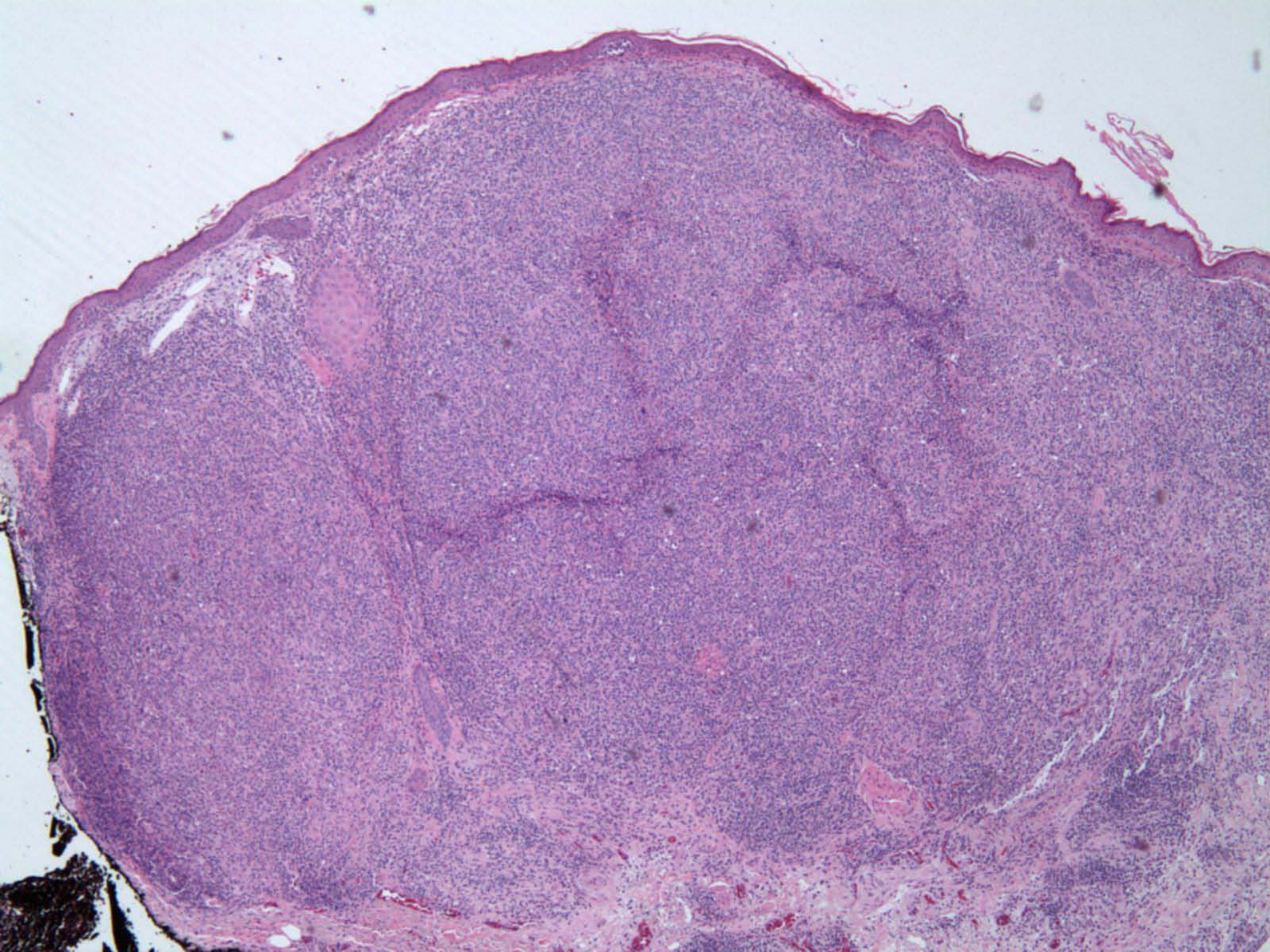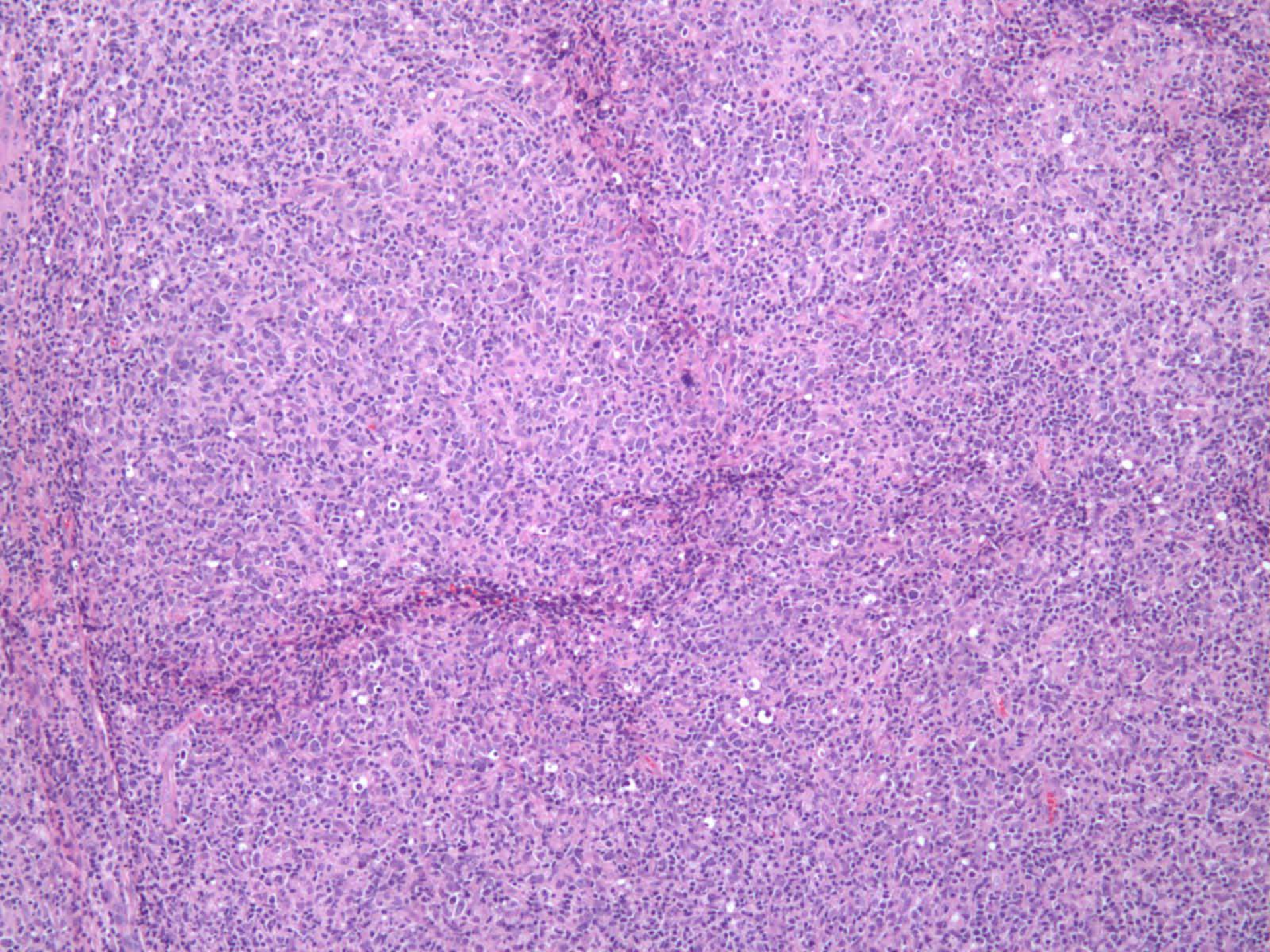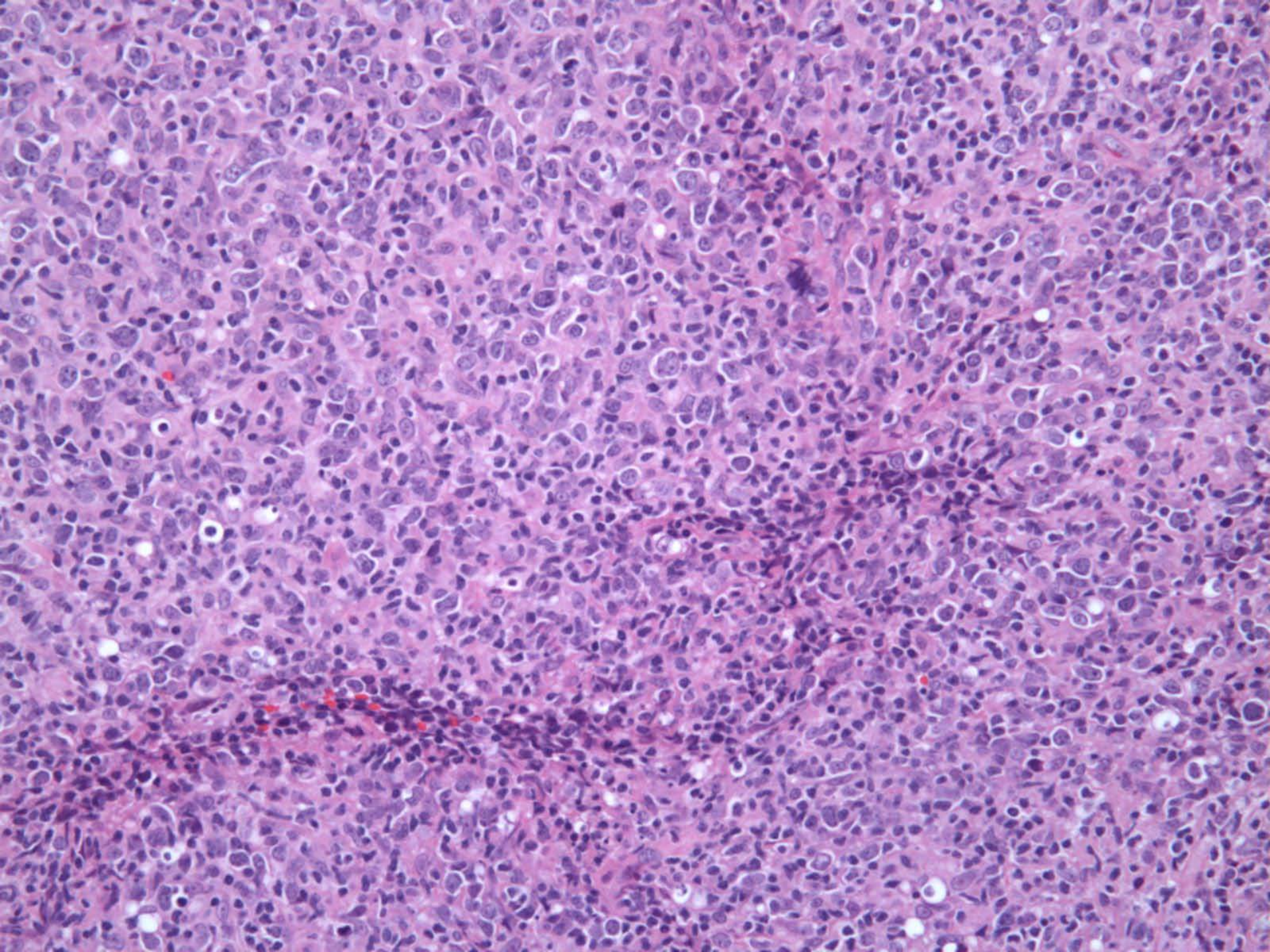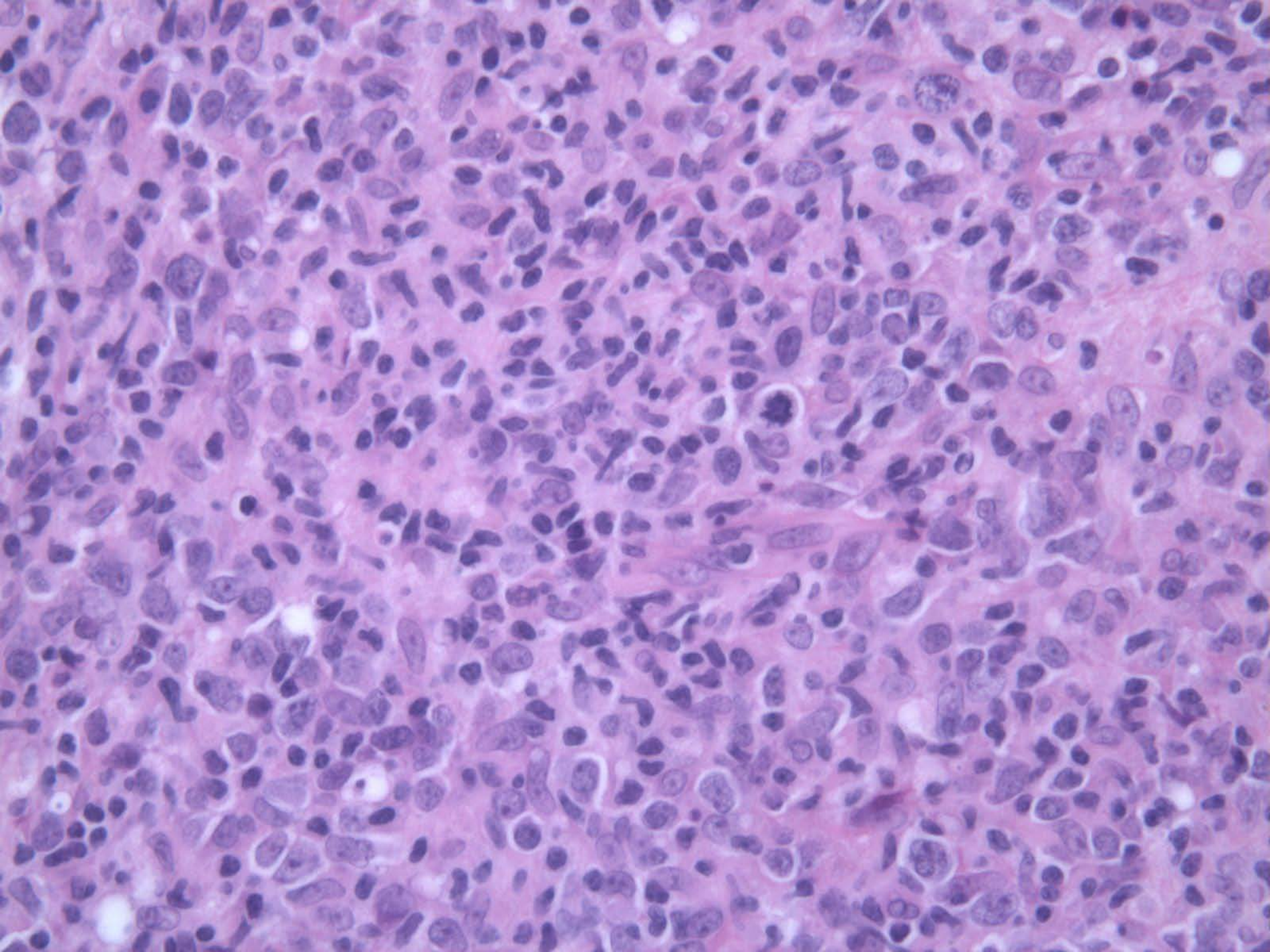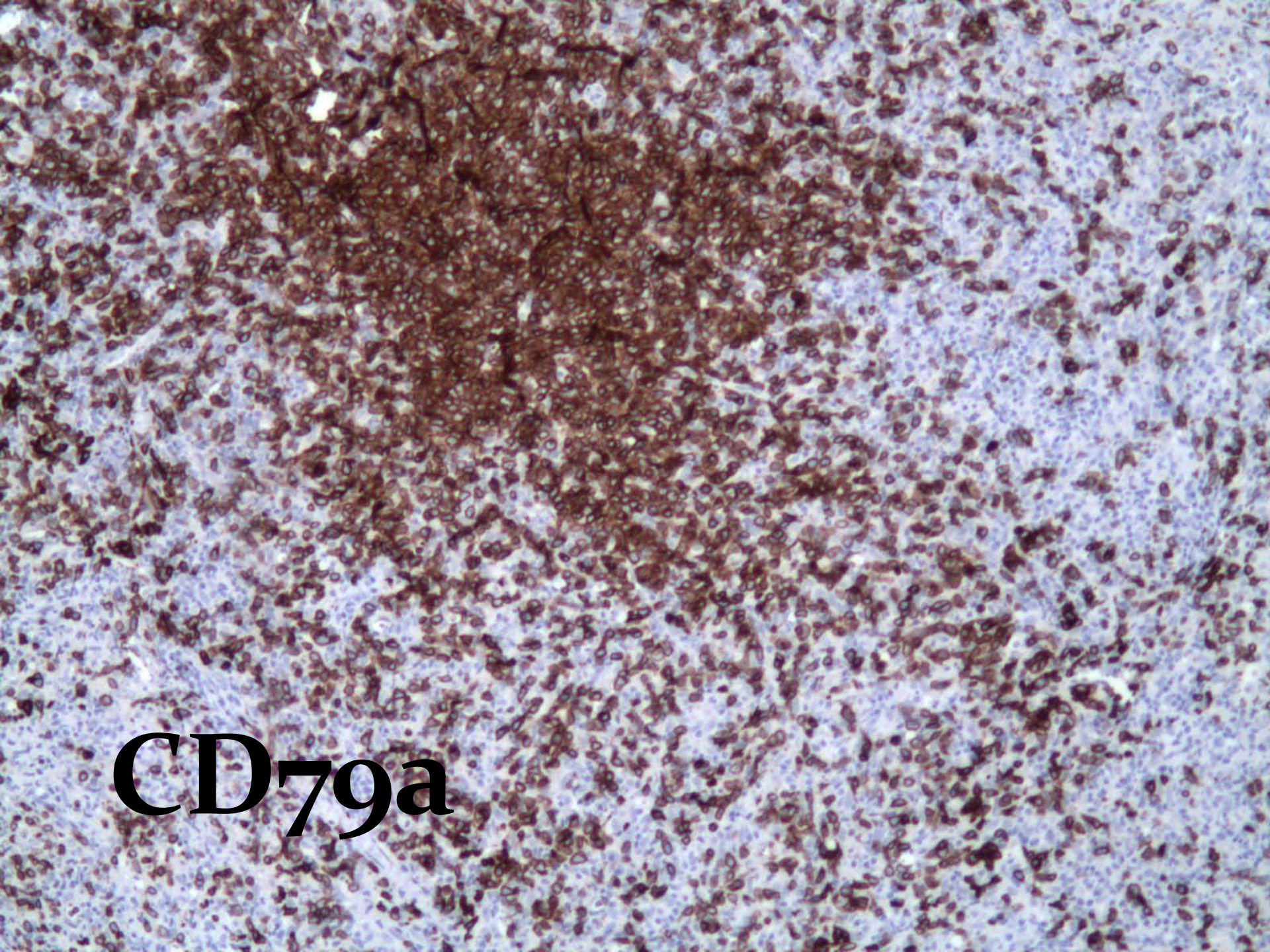


# Cutaneous B-Cell Lymphoma

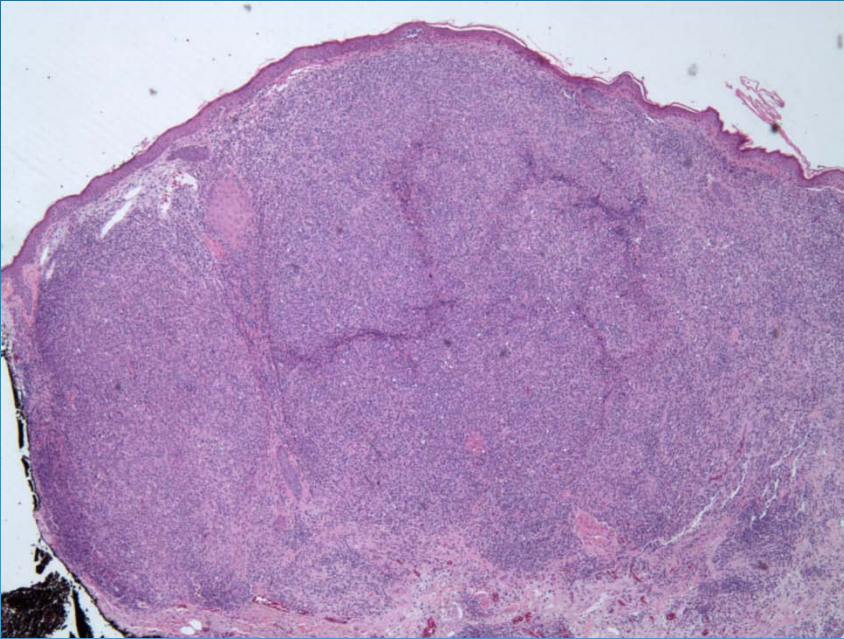




**CD79a**



# Pearls



- Dense bottom heavy monomorphic lymphoid infiltrate
- Should not see germinal centers or tingible body macrophages
- May have Grenz zone